

Pure laparoscopic pancreatoduodenectomy with initial approach to the superior mesenteric artery

Juan Santiago Azagra, Luca Arru, Sergio Estévez, Makkai-Popa Silviu-Tiberiu, Virginie Poulain, Martine Goergen

Centre Hospitalier de Luxembourg, Service de Chirurgie Générale et Mini-invasive, Luxembourg City, Luxembourg GD

Videosurgery Miniinv 2015; 10 (3): 450–457

DOI: 10.5114/wiitm.2015.54040

Abstract

Introduction: The “artery-first approach” (AFA) to the superior mesenteric artery allows an early assessment of resectability of pancreatic tumours and could improve the benefits of laparoscopy, reducing invasiveness, especially for unresectable tumours.

Aim: To describe our technique of pure laparoscopic pancreatoduodenectomy (PLPD) with the AFA, and to report the surgical outcomes of this procedure in a small series of 12 patients through a retrospective analysis of a prospectively collected database.

Material and methods: Twelve selected patients underwent elective full laparoscopic pancreatoduodenectomy with the AFA. The technical aspects of the procedure are described in detail and the included images facilitate the understanding of the procedure.

Results: The mean operative time was 300 min (range: 250–540 min). No intraoperative complications were observed. No conversion to laparotomy was necessary. The mean postoperative hospital stay was 18 days (range: 8–42). Mortality was null. There were 3 major complications at the 3rd post-operative month follow-up: 2 patients reporting a grade A pancreatic fistula and one biliary fistula.

Conclusions: Our work shows that pure laparoscopic pancreatoduodenectomy (PLPD) with the AFA is feasible, in selected patients. The AFA could improve on the advantages of laparoscopy in the identification of unresectable patients, and it also allows early control of vascular structures.

Key words: pancreatoduodenectomy, artery first approach, pure laparoscopy, feasibility, short-term outcomes, laparoscopy.

Introduction

In the last two decades, since the first laparoscopic pancreatoduodenectomy (LPD) was described in 1994 by Michel Gagner, the technique of pancreatoduodenectomy (PD) has been continuously evolving [1].

Current literature considers LPD a reliable and safe technique for selected patients [2], but also indicates that conversion rates to laparotomy remain high across different reports, varying between 10% to 40% [3–5].

The main difficulties of LPD are related to the vascular dissection, and thus the major controversies concern the assessment of resectability and implicitly the selection of patients.

Classically, in open surgery, venous resection is well accepted and should be performed, to achieve R0 resection, when it can be done safely. In contrast, resection of the superior mesenteric artery (SMA) is reported to increase postoperative morbidity and mortality rates without a remarkable improvement in survival, which meant that this radical approach has been largely abandoned [6, 7].

Address for correspondence

Luca Arru MD, Centre Hospitalier de Luxembourg, Service de Chirurgie Générale et Mini-Invasive, 4 Rue Barblé St, 1210 Luxembourg City, Luxembourg GD, phone: +35244112085, e-mail: lucaarrumd@gmail.com

Besides, it is well known that laparoscopic staging allows identification of metastatic disease, unrecognised on the preoperative computed tomography (CT) study, in about 10% of patients, sparing these individuals a laparotomy, without compromising the oncological prognosis and being accompanied by a low morbidity [8–11].

In light of this, the artery-first approach (AFA) to SMA can also be useful to assess the para-aortic nodal involvement. The presence of nodal metastasis at this level should prompt the surgeon to abandon a curative intent, except in the case of neuroendocrine tumours [12]. Furthermore, laparoscopic staging with the AFA could improve the intraoperative staging in the early stages of the procedure, before an irreversible step has been accomplished [13]. Also, during open surgery, the AFA is reported to reduce intraoperative blood loss and postoperative complications when compared with standard PD. However, none of the studies reports the number of resections abandoned owing to SMA invasion [14–18].

Aim

The aim of the article is to describe our technique of pure laparoscopic pancreatoduodenectomy (PLPD) with the AFA, and to report the surgical outcomes of this procedure in a small series of 12 patients through a retrospective analysis of a prospectively collected database.

Material and methods

Patient selection

A series of 12 patients were selected to undergo PLPD with the AFA, according to strict inclusion and exclusion criteria. The study was accepted by all patients, who signed an exhaustive informed consent form.

The inclusion criteria we used were as follows:

- tumour located in the head of the pancreas or in the duodenum;
- resectable tumour: resectability was evaluated by pre-operative spiral CT with virtual angiography in order to exclude vascular involvement, nodal and distant metastasis;
- intention to treat by PLPD with the AFA.

The exclusion criteria applied for the selection of the study group were the following:

- pre-operative evidence of vascular invasion, requiring open procedure to safely carry out the superior mesenteric vein (SMV) dissection/resection;
- peritoneal or hepatic metastasis;
- impossibility to achieve an R0 resection without multi-visceral resection.

For the purpose of our study pancreatic fistula was defined and classified according to the recommendations of the International Study Group of Pancreatic Fistula (ISGPF) [19]. Delayed gastric emptying (DGE) was defined, for the purpose of our study, as the inability to return to a standard diet by the end of the first postoperative week according to the definition proposed by the International Study Group for Pancreatic Surgery (ISGPS) [20].

Procedure

The patient is placed in the supine position with the legs in abduction. Under general anaesthesia, the pneumoperitoneum is induced at a pressure of 14 mm Hg using a Veress needle (Ethicon Endo-Surgery Inc., Cincinnati, OH) and the trocars are inserted under direct vision. The position of the surgeons and the placement of the trocars depend on the stage of the procedure, as shown in Figure 1.

Kocher manoeuvre

The surgeons and patient are placed as shown in Figure 1 A. The AFA technique that we employ was previously described by Partensky *et al.* for open surgery [12]. The absence of metastatic disease is confirmed by a complete laparoscopic exploration.

The procedure begins with the dissection of the hepatic flexure of the colon, which is mobilized and reflected downward (Photos 1.1–1.4), in order to obtain a wide Kocher manoeuvre, extended to the left side of the aorta. The dissection is then carried on to the inferior aspect of the pancreatic neck, in order to achieve a complete mobilisation of the third duodenal portion.

This approach allows the complete control of the SMA area – the inferior vena cava and the left renal vein, crossed by the SMA, are also exposed (Photos 1.5–1.10). Invasion of the SMA can thus be identified at an early stage of the procedure, preventing a useless macroscopic positive resection (R2). Furthermore, this approach allows easier identification and sparing of anatomical variants of the hepatic artery such as a right hepatic artery or a common hepatic artery originating from the SMA, which have

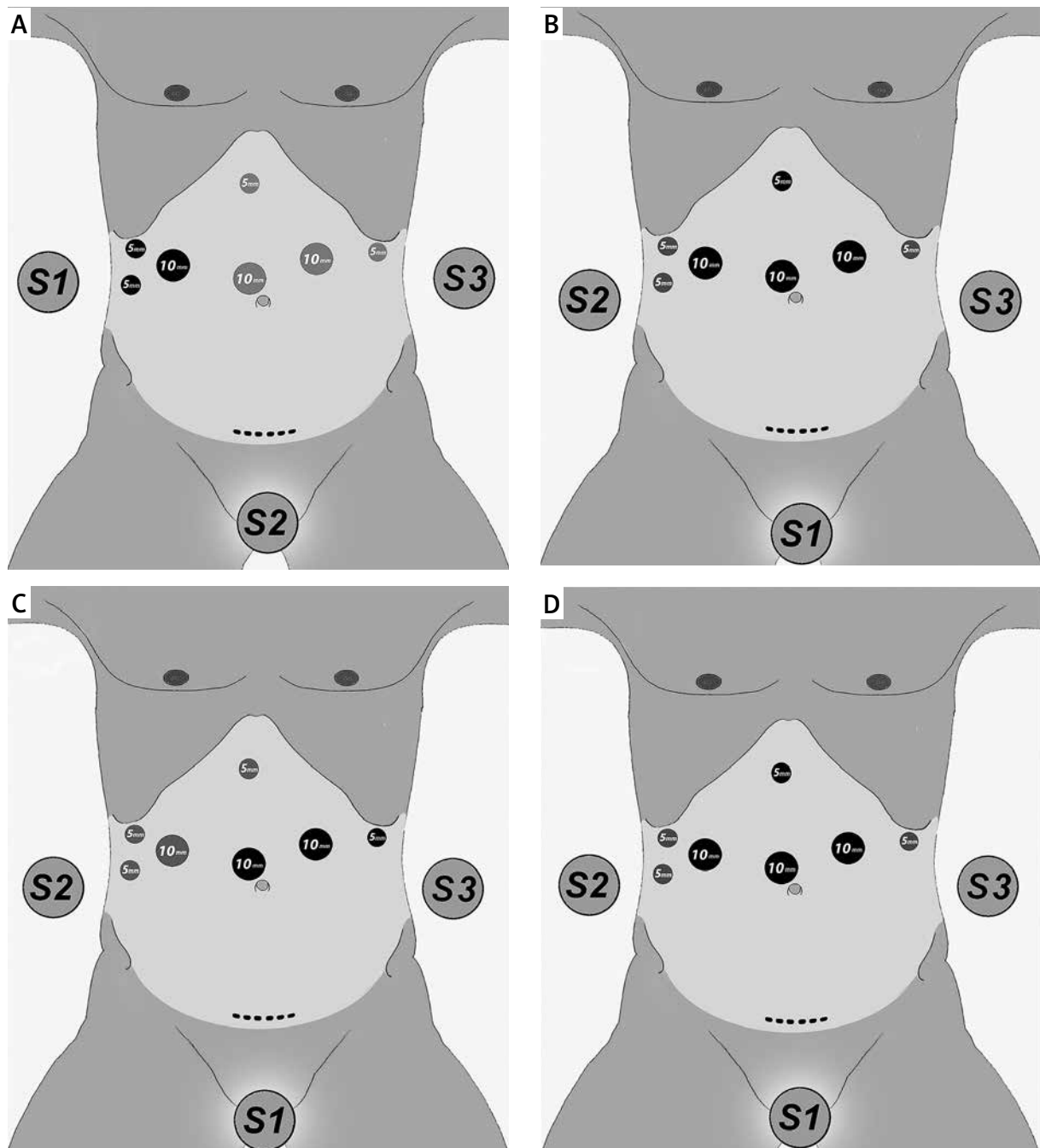


Figure 1. Operative team and trocar placement according to the operative stage. **A** – Kocher manoeuvre and AFA. **B** – Vascular dissection and pancreatic transaction. **C** – Treitz and uncinata process dissection. **D** – Biliary section and reconstruction. S1 – first surgeon; S2, S3 – assistants. The black dots represent the trocars used by the first surgeon for each stage of the procedure

to be carefully assessed during the preoperative radiologic study.

The nodal involvement is also assessed during this same operative phase, and in case of macroscopic evidence of nodal metastasis, an extemporaneous

nodal sample is sent for fresh-frozen section examination (Photos 1.11–1.12). In fact, the presence of peri-aortic lymph node metastases is considered a contraindication to curative PD, except in the case of neuroendocrine tumours [21, 22].

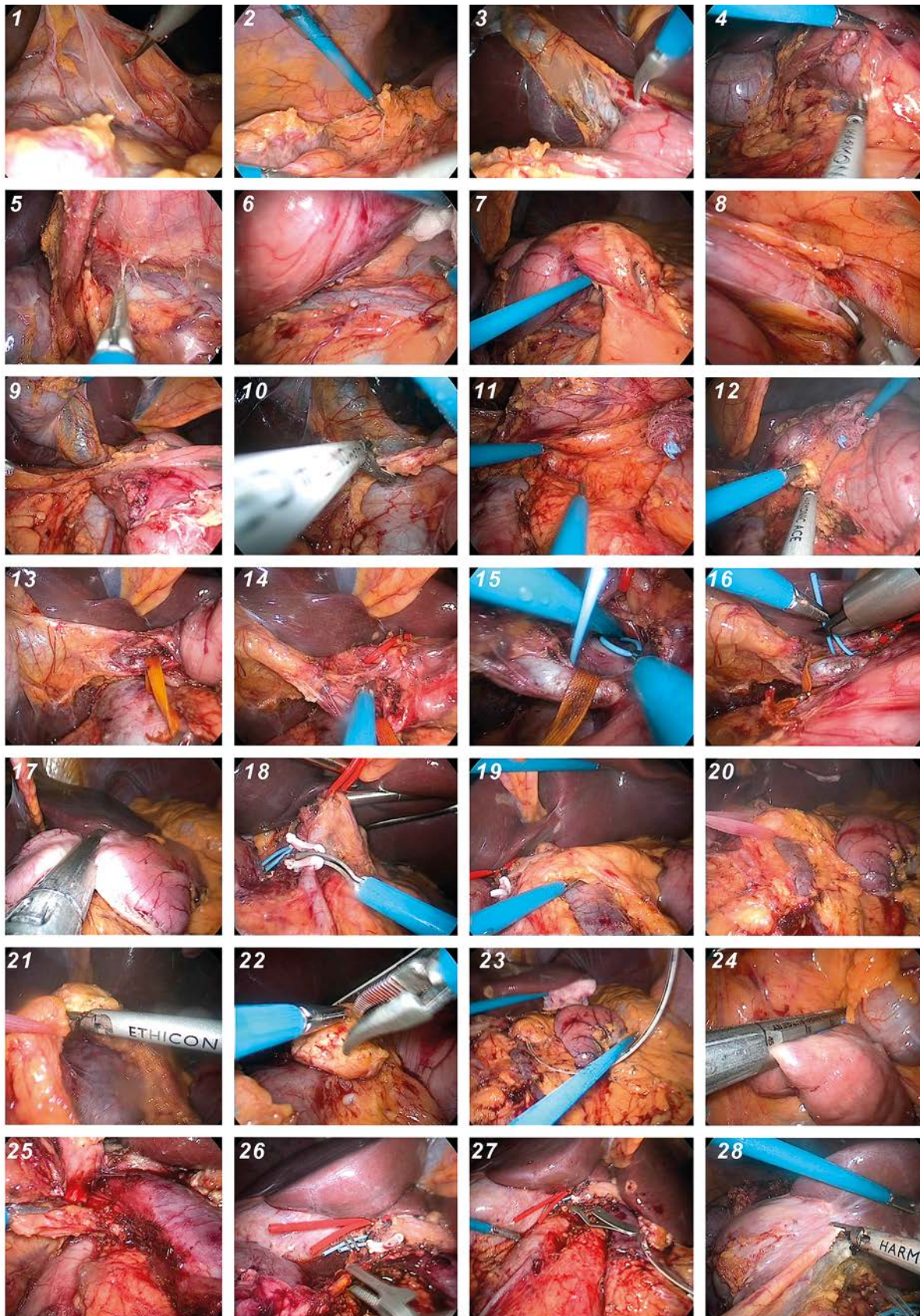


Photo 1. Resection stages of the procedure – explained in text

Pancreatic transection

The surgeon (S1) is positioned between the legs of the patient and his working trocars are placed as shown in Figure 1 B.

During the dissection of the hepatic pedicle, the common bile duct (Photo 1.13), the hepatic artery (Photo 1.14) and the portal vein are identified and isolated (Photos 1.15–1.16). A complete lymphadenectomy of the common hepatic artery, including station 12A, is carried out.

The pylorus is mobilized after the right gastroepiploic vessels and the pyloric artery is sectioned.

The stomach is then transected 2 cm proximally to the pylorus, using an articulated 45 mm stapler with a green cartridge (ECHELON FLEX Ethicon Endo-Surgery, Inc. – Cincinnati, OH, USA) (Photo 1.17).

The gastro-duodenal artery is sectioned after having been clipped with a Hem-o-Lok clip (Weck Surgical Instruments, Teleflex Medical, Durham, NC) (Photo 1.18).

The identification of Henle's trunk allows to identify the superior mesenteric vein (SMV), which is dissected, in order to carry out the pancreatic hanging manoeuvre, using a common textile vessel loop (Photos 1.19–1.20).

The pancreatic transection is then performed by use of a harmonic scalpel (Ultracision, Ethicon Endo-Surgery, Inc. – Cincinnati, OH, USA) (Photos 1.21–1.22).

A percutaneous catheter is placed into the distal Wirsung duct in order to evacuate the pancreatic secretion during the rest of the procedure. It will also be used for intraluminal drainage of the pancreaticojejunostomy (Photo 1.23).

Treitz and uncinata process dissection

The positions of surgeons and the placement of the trocars are shown in Figure 1 C.

The Treitz angle is dissected and the first jejunal loop is transected using an articulated 45 mm stapler with a blue cartridge (ECHELON FLEX Ethicon Endo-Surgery, Inc. – Cincinnati, OH, USA) (Photo 1.24). The duodenum is then retracted caudally.

The retroportal pancreatic lamina is divided from the right side of the superior mesenteric vein (SMV) and the portal vein (PV). The pancreatic head is retracted to the right side of the patient, in order to allow the dissection of the remaining connective tissue attachments of the uncinata process. The portal

branches are divided using metal clips and ultrasonic shears (Photo 1.25).

Biliary section

The surgeon (S1) places himself between the legs of the patient and the trocars are placed as shown in Figure 1 D.

The common bile duct is clamped before its section, in order to avoid bile spillage (Photos 1.26–1.27). Cholecystectomy is performed (Photo 1.28).

Reconstruction

The greater omentum can be transposed to isolate the anastomoses, allowing to avoid direct contact between the anastomoses and the mesenteric vessels (Photo 2.1).

Finally, the anastomoses are classically performed on the jejunal loop raised through the mesenteric defect, previously created by the dissection of the angle of Treitz (Photos 2.2–2.3):

- the pancreaticojejunostomy is performed in an end-to-side fashion: 4 to 6 simple cardinal stitches of 4/0 PDS are used for the Wirsung. Afterwards, 6 to 8 simple stitches are used to fix the pancreatic and jejunal serosa. The previous catheterization of the Wirsung, by a 3–6 French silicon drain, allows an accurate and targeted suture of the duct (Photos 2.4–2.8);
- the hepaticojejunostomy is performed in an end-to-side fashion: around 30 cm distally to the pancreaticojejunostomy. The posterior side of the anastomosis is done using separate stitches of 4/0 PDS; a running suture is performed on the anterior aspect of the anastomosis (Photos 2.9–2.12);
- the gastrojejunostomy is performed in a side-to-side fashion using mechanical suture: using an articulated 45 mm stapler with a green cartridge (ECHELON FLEX Ethicon Endo-Surgery, Inc. – Cincinnati, OH, USA) and manually placing a running suture (V-Loc 3/0, Covidien, Inc, Mansfield, Massachusetts, USA) to close the gastrojejunostomy (Photos 2.13–2.16).

Drainage is used systematically by means of two Penrose drains (Photos 2.17–2.18) and the specimen is extracted through a Pfannenstiel incision (Photos 2.19–2.20). Two expert surgeons performed all of these procedures, in “tandem” fashion: the resection was carried out by one and the reconstruction by the other.

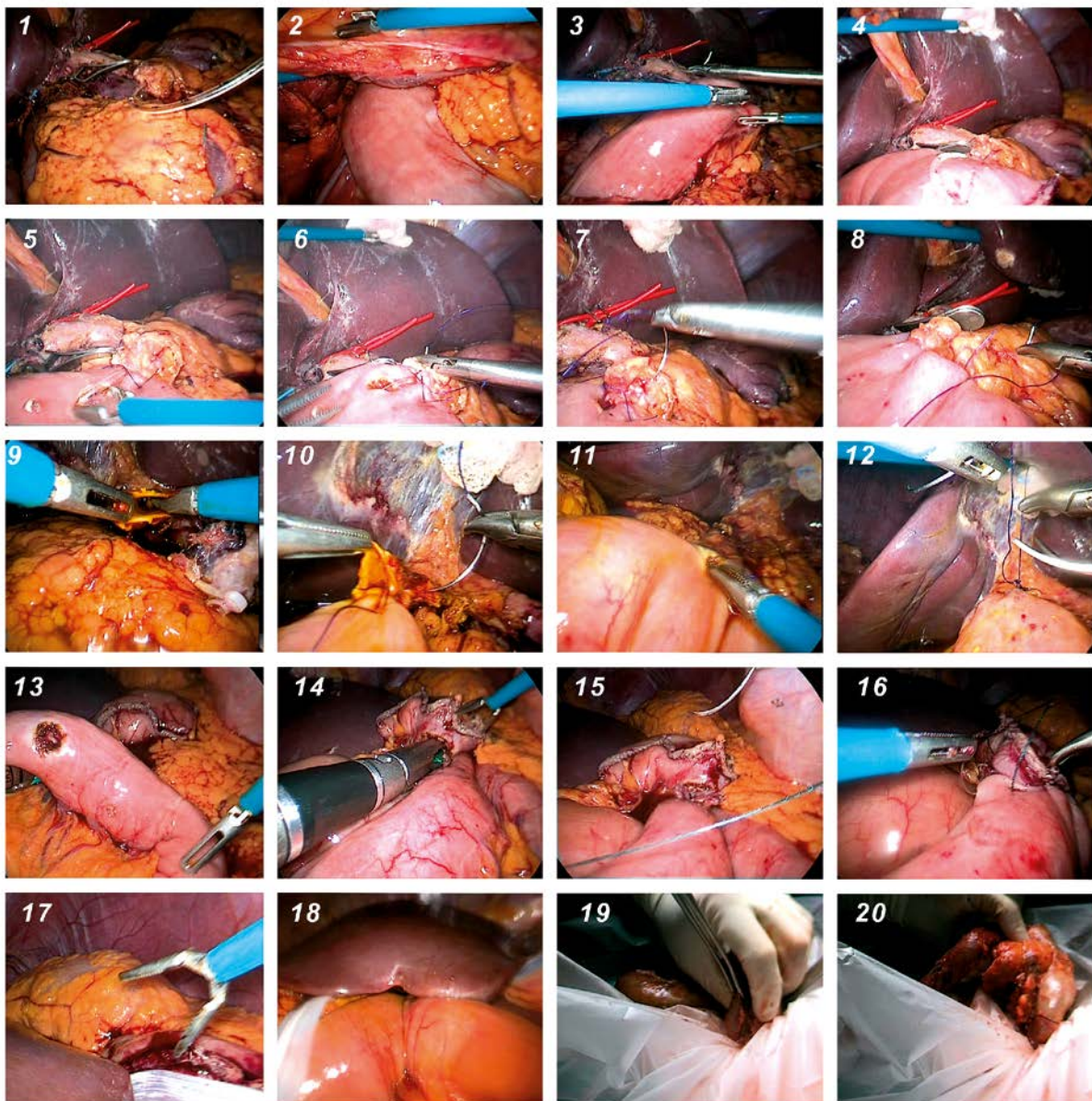


Photo 2. Reconstruction stages of the procedure – explained in text

Results

The demographic data, operative and post-operative results of the series are summarised in Table I.

Three patients were excluded from the series, initially composed of 15 patients, due to the intraoperative detection of liver metastases in 2 cases and due to extended vascular infiltration of the SMA in one case, not previously described on the preoperative CT scan.

No open conversion, or haemorrhage requiring blood transfusions, was observed in this series.

Concerning the vascular variants, the right hepatic artery originated from the SMA in only one patient, which was consistent with the preoperative CT-scan description. There was no mortality at the 3rd post-operative month (POM). There were three complications: two grade A pancreatic fistulas according to the ISGPF classification and one biliary fistula [19].

Five patients developed a DGE: 2 grade B and 3 grade A, according to the ISGPS classification [20]. All complications were resolved conservative-

Table I. Summary of demographic, operative and post-operative data of the patients included in the study

Parameter	Results
Demographic data:	
Patients, <i>n</i>	12
Male/female gender, <i>n</i>	5/7
Age, mean (range) [years]	62 (55–78)
BMI, mean (range) [kg/m ²]	26 (23–30)
Operative data:	
Operative time, mean (range) [min]	300 (250–540)
Estimated blood loss, mean (range) [ml]	180 (100–600)
No. of lymph nodes retrieved (range)	17 (8–31)
Post-operative data:	
Hospital stay, mean (range) [day]	18 (8–42)
Mortality at 3 rd post-operative month (%)	0
Complications:	
Pancreatic fistula	2 patients, (grade A)
Biliary fistula	1 patient
Blood transfusion	0
Port site metastasis	0/0
Re-intervention at 3 rd post-operative month	0

ly and did not require surgical intervention or any endoscopic or radiological interventional procedures.

The histological findings are shown in Table II.

All patients underwent a whole body scan in the 3rd POM. None of them developed local recurrence at this time. No port site metastases were observed. No internal or trocar hernias were reported.

Discussion

Despite conflicting opinions regarding LPD in the beginning, this procedure has gained increasing acceptance during the last decade [2, 23].

The increasing number of LPD recently reported in the world attests to the safety, the effectiveness and the benefits of laparoscopy, even in terms of oncological outcomes [24–26].

Table II. Summary of pathology findings in the resection specimens

Diagnosis	No. of cases
Pancreatic ductal adenocarcinoma	9
Neuroendocrine carcinoma	1
Metastatic renal cell carcinoma	1
Duodenal adenocarcinoma	1
Specimen characteristics:	
Tumour size, mean (range) [cm]	3 (1.5–7)
RO resection, <i>n</i> (%)	9 (75)
Regional lymph node metastases, <i>n</i> (%)	7 (58)

When compared to open surgery, the operative time is the only factor that is in favour of laparoscopy. In contrast, intraoperative blood loss, transfusion need, length of hospital stay and intensive care unit (ICU) stay, and wound infection rate all show significant differences favouring LPD [24].

However, a great number of publications have been reporting significant differences in technicality and surgical approach, limiting the standardization and the transmission of the technique.

Considering that surgical exploration plays a key role for the final assessment of resectability, our team adopted the laparoscopic AFA, which also allows safe vascular control and provides minor surgical invasiveness for unresectable tumours, with the following advantages:

- it allows dissection of the SMA by a posterior approach, and exploration of the SMV and PV confluent, with the well-known benefits of laparoscopic magnification of the field of view;
- it allows a total resection of the retro-pancreatic tissue, performing the dissection from the right to the left and from the back to the front;
- it facilitates the dissection and the sparing of an aberrant hepatic artery, both right and common, coming from the SMA, which should be previously detected on triple-phase CT assessment;
- it allows the resection to be performed only when the oncological assessment is completed, sparing an unnecessary laparotomy.

Finally, the stressful effort of the surgeon, due to the long operative time, was avoided in our study by using the “tandem team” concept: two different surgeons performing resection and reconstruction, which had no negative impact in our series.

Conclusions

Laparoscopic pancreatoduodenectomy is feasible and adequate in terms of oncological outcomes. It may be performed in selected patients, by highly skilled laparoscopic teams, with a wide experience in pancreatic surgery.

Pure laparoscopic pancreatoduodenectomy with the AFA could increase the advantage of laparoscopy, allowing early control of vascular structures, avoiding unnecessary resections and bleeding complications.

Further investigation is necessary to obtain a wide awareness of the benefits of PLPD and to clarify the selection criteria of the patients.

Conflict of interest

The authors declare no conflict of interest.

References

- Gagner M, Pomp A. Laparoscopic pylorus-preserving pancreatoduodenectomy. *Surg Endosc* 1994; 8: 408-10.
- Palanivelu C, Rajan PS, Rangarajan M, et al. Evolution in techniques of laparoscopic pancreaticoduodenectomy: a decade long experience from a tertiary center. *J Hepatobiliary Pancreat Surg* 2009; 16: 731-40.
- Gumbs AA, Rodriguez Rivera AM, Milone L, et al. Laparoscopic pancreatoduodenectomy: a review of 285 published cases. *Ann Surg Oncol* 2011; 18: 1335-41.
- Gagner M, Palermo M. Laparoscopic Whipple procedure: review of the literature. *J Hepatobiliary Pancreat Surg* 2009; 16: 726-30.
- Zureikat AH, Breaux JA, Steel JL, et al. Laparoscopic pancreaticoduodenectomy be safely implemented? *J Gastrointest Surg* 2011; 15: 1151-7.
- Nakao A, Takeda S, Inoue S, et al. Indication and techniques of extended resection for pancreatic cancer. *World J Surg* 2006; 30: 976-82.
- Amano H, Miura F, Toyato N, et al. Is pancreatectomy with arterial reconstruction a safe and useful procedure for locally advanced pancreatic cancer. *J Hepatobiliary Pancreat Surg* 2009; 16: 850-7.
- Muniraj T, Barve P. Laparoscopic staging and surgical treatment of pancreatic cancer. *N Am J Med Sci* 2013; 5: 1-9.
- Urbach DR, Swanstrom LL, Hansen PD. The effect of laparoscopy on survival in pancreatic cancer. *Arch Surg* 2002; 137: 191-9.
- Winner M, Allendorf JD, Saif MW. An update on surgical staging of patients with pancreatic cancer highlights from the "2012 ASCO Gastrointestinal Cancers Symposium". San Francisco, CA, USA. *J Pancreas (Online)* 2012; 10: 13: 143-6.
- D'Angelica M, Fong Y, Weber S, et al. The role of staging laparoscopy in hepatobiliary malignancy: prospective analysis of 401 cases. *Ann Surg Oncol* 2003; 10: 183-9.
- Partensky C. Abord premier de l'artère mésentérique supérieure au cours de la duodéno pancréatectomie céphalique. *J Chir* 2008; 145: 598-600.
- Sanjay P, Takaori K, Govil S, et al. 'Artery-first' approaches to pancreatoduodenectomy. *Br J Surg* 2012; 99: 1027-35.
- Dumitrascu T, David L, Popescu I. Posterior versus standard approach in pancreatoduodenectomy: case-match study. *Langenbecks Arch Surg* 2010; 395: 677-84.
- Figueroas J, Albiol M, Lopez-Ben S, et al. Cephalic duodenopancreatectomy in periampullary tumours. Dissection of the superior mesenteric artery as in initial approach. Description of the technique and assessment of our experience. *Cir Esp* 2008; 83: 186-93.
- Shrikhande SV, Barreto SG, Bodhankar YD, et al. Superior mesenteric artery first combined with uncinata process approach versus uncinata process first approach in pancreatoduodenectomy: a comparative study evaluating perioperative outcomes. *Langenbeck's Archives of Surgery* 2011; 396: 1205-12.
- Lupaşcu C, Moldovanu R, Andronic D, et al. Posterior approach pancreaticoduodenectomy: best option for hepatic artery anatomical variants. *Hepatogastroenterology* 2011; 58: 2112-4.
- Rose JB, Rocha F, Alseidi A, Helton S. Posterior 'superior mesenteric artery first' approach for resection of locally advanced pancreatic cancer. *Ann Surg Oncol* 2014; 21: 1927-8.
- Pratt WB, Maithel SK, Vanounou T, et al. Clinical and economic validation of the International Study Group of Pancreatic Fistula (ISGPF) classification scheme. *Ann Surg* 2007; 245: 443-51.
- Wente MN, Bassi C, Dervenis C, et al. Delayed gastric emptying (DGE) after pancreatic surgery: a suggested definition by the International Study Group of Pancreatic Surgery (ISGPS). *Surgery* 2007; 142: 761-8.
- Shimada K, Sakamoto Y, Sano T, et al. The role of paraaortic lymph node involvement on early recurrence and survival after macroscopic curative resection with extended lymphadenectomy for pancreatic carcinoma. *J Am Coll Surg* 2006; 203: 345-52.
- Yoshida T, Matsumoto T, Sasaki A, et al. Outcome of paraaortic node-positive pancreatic head and bile duct adenocarcinoma. *Am J Surg* 2004; 187: 736-40.
- Azagra-Soria JS, Facy O, Goergen M, et al. Minimally invasive pancreatic resection. *eWJMS* 2012; 2: 28-31.
- Nakamura M, Nakashima H. Laparoscopic distal pancreatectomy and pancreatoduodenectomy: is it worthwhile? A meta-analysis of laparoscopic pancreatectomy. *J Hepatobiliary Pancreat Sci* 2013; 20: 421-8.
- Pericleous S, Middleton N, McKay SC, et al. Systematic review and meta-analysis of case-matched studies comparing open and laparoscopic distal pancreatectomy: is it a safe procedure? *Pancreas* 2012; 41: 993-1000.
- Kendrick ML, Cusati D. Total laparoscopic pancreaticoduodenectomy. *Arch Surg* 2010; 145: 19-23.

Received: 29.04.2015, accepted: 15.07.2015.